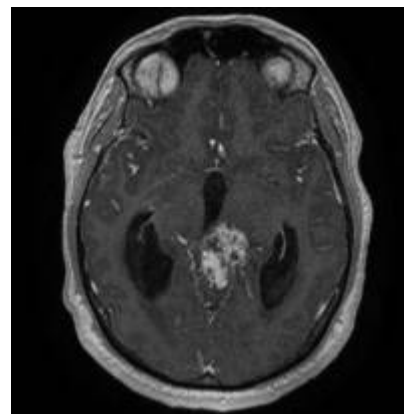


# Velum interpositum meningioma

*J.Sales-Llopis*

*Neurosurgery Service, Alicante University General Hospital, Alicante Institute for Health and Biomedical Research (ISABIAL - FISABIO Foundation), Alicante, Spain.*



The [velum interpositum meningioma](#) is a [intraventricular meningioma](#) of the [third ventricle](#), often described as [pineal region meningioma](#) or [third ventricle meningioma](#).

Pineal region meningioma are extremely rare and include [falcotentorial meningioma](#) and velum interpositum meningiomas. It is very difficult to discriminate between these two lesions and description of the clinical presentation and the surgical technique in approaching these tumors is limited <sup>1)</sup>.

## Epidemiology

True meningiomas of the velum interpositum (without any dural involvement) are indeed exceedingly uncommon. Radiologically, they may mimic any third ventricular or pineal region tumor depending on the exact site of origin and direction of growth <sup>2)</sup>.

## Etiology

They arise from the posterior portion of the velum interpositum, the double layer of pia mater that forms the roof of the third ventricle.

Knowing from which leaflet the meningioma originates and thus its relationships with the internal cerebral and Galen veins, may help in choosing the surgical approach.

Reviewing the literature, of the 22 reported cases of velum interpositum meningiomas, sufficient information regarding the precise location of the origin of the tumor was provided in 14 cases, all of which were from the inferior leaflet <sup>3)</sup>.

They are supplied by the [posterior choroidal artery](#) and displace the Galenic venous complex (GVC) postero-superiorly <sup>4)</sup>.

## Classification

They have been classified into dorsal and ventral leaf lesions.

Dorsal leaf meningiomas push the vein of Galen ventrally while ventral leaf meningiomas push the venous complex dorsally, a subtle distinction is not possible in the large/giant lesions <sup>5)</sup>.

## Diagnosis

Meningiomas of the velum interpositum are extremely unusual and difficult to diagnose. They usually present as pineal or posterior third ventricular masses <sup>6)</sup>.

see [Falcotentorial meningioma](#)

## Treatment

Although Lozier et al. <sup>7)</sup> describe radiological imaging features (especially the course of the internal cerebral veins) in preoperatively differentiating these tumors, the information may not always be forthcoming and, even when available, may not always help differentiate them from other intraventricular meningiomas. What is however critical is to appreciate the venous anatomy (which may be grossly distorted) and preserve the veins during surgery. The surgical approach is dictated by the location and extent of the lesion

They can be safely managed with the use of [occipital transtentorial approach](#) (OTT) or [infratentorial supracerebellar approach](#) <sup>8)</sup>.

OTT is the preferable approach for large-to-giant meningiomas as it provides a wider corridor and better delineation of tumor-neurovascular arachnoidal interface <sup>9)</sup>.

Preservation of the deep venous system is crucial and complications can often be fatal. Although challenging, complete surgical excision is curative for the grade I lesions, and should be attempted. Recovery is often uneventful (and satisfying) if the deep venous structures are preserved.

For a giant velum interpositum meningioma Moiyadi et al. selected the transcortical transventricular transchoroidal approach <sup>10)</sup>.

## Case reports

### 2015

A 40-year-old male with a meningioma arising from the superior leaflet of the velum interpositum. The tumor was resected successfully using the [infratentorial supracerebellar approach](#).

Champagne et al. report the first case of velum interpositum meningioma arising from the superior

leaflet and give a potential explanation as to why meningiomas of the velum interpositum occur more commonly on the inferior leaflet. Distinguishing from which of the two leaflets the tumor originates may influence the surgical strategy <sup>11)</sup>.

## 2012

A3-year-old girl with a giant velum interpositum meningioma that was completely excised with excellent outcome. This is probably the youngest such case reported <sup>12)</sup>.

## 2007

One of these cases was a five years-old girl and the other a one year-old boy. No specific clinical presentation or tomographic examinations findings was identified before treatment, suggestive of a diagnosis of meningioma. The clinical and laboratory features were very similar to the most common tumors of the pineal region. Prior to the surgery, the histology of these tumors was not suspected. Both patients underwent direct surgery and complete removal was achieved by a [occipital transtentorial approach](#). The tumors originated from velum interpositum in both cases. At the follow up, one case presented with recurrence six years later, and she underwent a reoperation with total resection without morbidity. Long-term follow up presented no other recurrences <sup>13)</sup>.

## 2003

The authors review the literature concerning these meningiomas and present a case in which the lesion was resected via the supracerebellar-infratentorial approach. The relationship of the tumor to the deep venous system and the splenium of the corpus callosum guides the selection of the most advantageous surgical approach. Posterior displacement of the internal cerebral veins demonstrated on preoperative imaging provides a strong rationale for use of the supracerebellar-infratentorial approach <sup>14)</sup>.

## 1995

In 2 pineal region meningiomas, preoperative work-up revealed that both tumors received their main blood supply from the posterior lateral choroidal arteries and were therefore originating from the velum interpositum cerebri (superior tela choroidea) <sup>15)</sup>.

## 1979

Loss of upper and lower homonymous sectors in the visual field, and wasting of corresponding sectors in the retinal nerve fibre layer, followed ligation of the distal part of the anterior choroidal artery in a patient with a meningioma of the velum interpositum. Clinical and radiological evidence indicated that the visual pathway was damaged within that part of the lateral geniculate body that is served by the anterior choroidal artery <sup>16)</sup>.

The clinical presentation, radiological findings, and surgical management of two cases of meningioma arising from the velum interpositum without dural attachment are described. The true nature of these tumors was not suspected despite extensive preoperative diagnostic evaluation. A total removal was effected in both cases with the use of the operating microscope and a posterior fossa approach to the pineal region. A review of similar cases from the English literature is presented <sup>17)</sup>.

## References

1)

Nowak A, Dziedzic T, Czernicki T, Kunert P, Marchel A. Falcotentorial and velum interpositum meningiomas: two distinct entities of the pineal region. *Neurol Neurochir Pol.* 2014;48(6):397-402. doi: 10.1016/j.pjnns.2014.09.009. PubMed PMID: 25482250.

2) 10) 12)

Moiyadi AV, Shetty P. Giant velum interpositum meningioma in a child. *Indian J Med Paediatr Oncol.* 2012 Jul;33(3):173-5. doi: 10.4103/0971-5851.103147. PubMed PMID: 23248425; PubMed Central PMCID: PMC3523476.

3) 11)

Champagne PO, Bojanowski MW. Meningioma of the superior leaflet of the velum interpositum: A case report. *Surg Neurol Int.* 2015 Apr 22;6(Suppl 3):S132-5. doi: 10.4103/2152-7806.155703. eCollection 2015. PubMed PMID: 25949856.

4) 6) 7) 14)

Lozier AP, Bruce JN. Meningiomas of the velum interpositum: surgical considerations. *Neurosurg Focus.* 2003 Jul 15;15(1):E11. Review. PubMed PMID:15355013.

5) 9)

Behari S, Das KK, Kumar A, Mehrotra A, Srivastava AK, Sahu RN, Jaiswal AK. Large/giant meningiomas of posterior third ventricular region: falcotentorial or velum interpositum? *Neurol India.* 2014 May-Jun;62(3):290-5. doi:10.4103/0028-3886.136934. PubMed PMID: 25033852.

8)

Nowak A, Dziedzic T, Czernicki T, Kunert P, Marchel A. Falcotentorial and velum interpositum meningiomas: two distinct entities of the pineal region. *Neurol Neurochir Pol.* 2014;48(6):397-402. doi: 10.1016/j.pjnns.2014.09.009. Epub 2014 Oct 18. PubMed PMID: 25482250.

13)

Matushita H, Pinto FC, Plese JP. Meningiomas of pineal region in children. *Arq Neuropsiquiatr.* 2007 Dec;65(4A):1000-6. PubMed PMID: 18094863.

15)

Mallucci CL, Obukhov S. Successful removal of large pineal region meningiomas: two case reports. *Surg Neurol.* 1995 Dec;44(6):562-6. PubMed PMID: 8669033.

16)

Frisén L. Quadruple sectoranopia and sectorial optic atrophy: a syndrome of the distal anterior choroidal artery. *J Neurol Neurosurg Psychiatry.* 1979 Jul;42(7):590-4. PubMed PMID: 479897; PubMed Central PMCID: PMC490271.

17)

Rozario R, Adelman L, Prager RJ, Stein BM. Meningiomas of the pineal region and third ventricle. *Neurosurgery.* 1979 Oct;5(4):489-5. PubMed PMID: 534055.

From:

<https://neurosurgerywiki.com/wiki/> - **Neurosurgery Wiki**

Permanent link:

[https://neurosurgerywiki.com/wiki/doku.php?id=velum\\_interpositum\\_meningioma](https://neurosurgerywiki.com/wiki/doku.php?id=velum_interpositum_meningioma)

Last update: **2024/06/07 02:53**

