

Trigone tumor

The [atrium](#) of the [lateral ventricle](#) is often affected by tumors, and some patients with these tumors suffer neurological deficits, including hemiparesis after surgery.

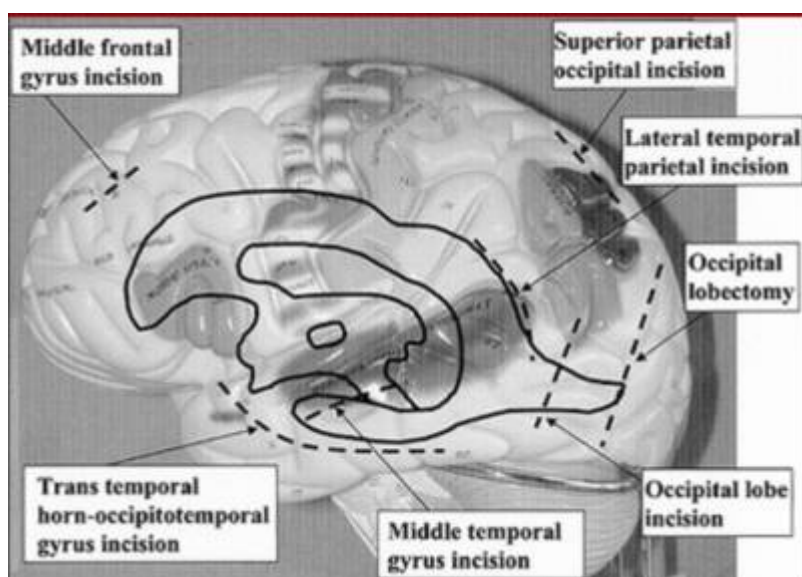
Classification


[Trigone meningioma](#).

The ventricular atrium is the most common site for the occurrence of choroid plexus papillomas, meningiomas, and ependymomas, and arteriovenous malformations.

Treatment

Lesions can be challenging to resect because of their inherently deep location and the proximity of the choroidal arteries, the deep venous system, and, especially when in the dominant hemisphere, the adjacent cerebral cortex ^{1) 2)}.



The occurrence of tumors arising at the trigone of the lateral ventricle is comparatively infrequent 

Cystic lesions in the atrium (trigone) of the [lateral ventricle](#) may become symptomatic due to obstruction of physiological CSF circulation and/or from mass effect on adjacent structures.

Importance

Neurosurgeons must be aware of the possibility of [lateral posterior choroidal artery](#) (LPChA) territory infarction during surgery in the atrial or periatrinal regions caused by subependymal artery obstruction

after manipulating or coagulating the [choroid plexus](#) near the atrium ³⁾.

Approaches

Conventional approaches to the [atrium](#) of the [lateral ventricle](#) may be associated with [complications](#) related to direct cortical injury or brain retraction and present unique neurosurgical challenges due to the [eloquent](#) nature of the surrounding anatomy ⁴⁾.

The selection of the best operative approach to this site is still controversial ⁵⁾.

[Contralateral Transfalcine Transprecuneus Approach](#)

[Supracerebellar transtentorial approach](#)

[Posterior interhemispheric transprecuneus gyrus approach](#)

[Posterior parietooccipital interhemispheric approach](#)

[Supracerebellar transtentorial transcollateral sulcus approach](#)

[Endoscopic Posterior Transcortical Keyhole Approach](#)

[Superior parietooccipital approach](#)

[Middle temporal gyrus approach](#)

[Lateral temporoparietal approach](#)

[Occipital transcallosal approach](#)

They are more or less associated with neurological deficits or a narrow working corridor ^{6) 7) 8)}.

Jeelani et al describe a novel approach to the atrium through a retrosigmoid transtentorial transcollateral sulcus corridor.

Bilateral retrosigmoid craniotomies were performed on 4 formalin-fixed, colored latex-injected human cadaver heads (a total of 8 approaches). Microsurgical dissections were performed under 3× to 24× magnification, and endoscopic visualization was provided by 0° and 30° rigid endoscope lens systems. Image guidance was provided by coupling an electromagnetic tracking system with an open source software platform. Objective measurements on cortical thickness traversed and total depth of exposure were recorded. Additionally, the basal occipitotemporal surfaces of 10 separate cerebral hemisphere specimens were examined to define the surface topography of sulci and gyri, with attention to the appearance and anatomical patterns and variations of the collateral sulcus and the surrounding gyri.

The retrosigmoid approach allowed for clear visualization of the basal occipitotemporal surface. The collateral sulcus was identified and permitted easy endoscopic access to the ventricular atrium. The conical corridor thus obtained provided an average base working area of 3.9 cm² at an average depth of 4.5 cm. The mean cortical thickness traversed to enter the ventricle was 1.4 cm. The intraventricular anatomy of the ipsilateral ventricle was defined clearly in all 8 exposures in this

manner. The anatomy of the basal occipitotemporal surface, observed in a total of 18 hemispheres, showed a consistent pattern, with the collateral sulcus abutted by the parahippocampal gyrus medially, and the fusiform and lingual gyrus laterally. The collateral sulcus was found to be caudally bifurcated in 14 of the 18 specimens.

The retrosigmoid supracerebellar transtentorial transcollateral sulcus approach is technically feasible. This approach has the potential advantage of providing a short and direct path to the atrium, hence avoiding violation of deep neurovascular structures and preserving eloquent areas. Although this approach appears unconventional, it may provide a minimally invasive option for the surgical management of selected lesions within the atrium of the lateral ventricle ⁹⁾.

Case series

Andoh et al. have operated on eight cases with trigonal tumors during a 10-year period. Four cases were true intraventricular tumors arising from the ventricular walls, consisting of two meningiomas, one cavernous angioma, and one choroid plexus papilloma. On the other hand, the remaining four cases were paraventricular tumors originating in the adjacent brain and consisted of three astrocytomas and one glioblastoma multiforme. Although these trigonal tumors were readily detected with computed tomographic (CT) scanning, differential diagnosis was difficult because of their similar appearances on CT scans. The initial symptoms were headache in seven, and the neurological examination revealed personality changes, choked disc, visual field defects, hemiparesis, etc., in four, and no deficits in the remaining four cases. All cases were operated on via superior or middle temporal gyrus incision, and the surgical results were good except for one case who died of postoperative brain edema. In the four cases with tumors located in the dominant hemisphere, two were left with sensory aphasia, dyslexia, dyscalculia, and hemianopsia which improved within 6 months. In these two cases, postoperative CT scans revealed cerebrospinal fluid retention with severe edema along the surgical route which disappeared spontaneously within 3 months. We consider that the temporal gyrus incision was the safest approach, even though the tumor was located in the dominant side ¹⁰⁾.

Case reports

A 62-yr-old woman presented with incidentally detected left trigonal mass by magnetic resonance imaging (MRI) performed during workup for left-sided hearing loss and vertigo of 5-yr duration. Due to persistent dizziness, headache, and progressive enlargement of the tumor in follow-up scans, operation was planned. Because the tumor extended superiorly, a superior parietal lobule approach was selected. She underwent a left parietal craniotomy. A strip electrode was used to localize the motor and sensory regions, and neuronavigation was used to confirm the entry site. A small transsulcal corticotomy was performed posterior to a large cortical vein. The tumor was pinkish in color with a well-defined capsule. It was centrally debulked by using curettes, pituitary forceps, and the ultrasonic aspirator. Tumoral blood supply from the choroid plexus and the posterior choroidal vessels were cauterized and divided. Additional blood supply coming from the anterior choroidal vessels was also found and cauterized. After circumferential dissection of the tumor capsule, the tumor was removed completely. The pathology indicated WHO Grade I meningioma. The patient had mild expressive and receptive aphasia postoperatively, but improved progressively. The postoperative MRI showed total resection with no evidence of brain injury. At 3-mo follow-up, the speech was normal; she was independent for all daily activities, but had not yet returned to work.

(Karnofsky score 80). This 3-D video shows the technical nuances of microsurgical resection of an intraventricular tumor through a narrow brain corridor. Informed consent was obtained from the patient prior to the surgery that included videotaping of the procedure and its distribution for educational purposes. All relevant patient identifiers have also been removed from the video and accompanying radiology slides ¹¹⁾.

1)

Izci Y, Seçkin H, Ateş O, Başkaya MK: Supracerebellar transtentorial transcollateral sulcus approach to the atrium of the lateral ventricle: microsurgical anatomy and surgical technique in cadaveric dissections. *Surg Neurol* 72: 509–514, 2009

2)

Marcus HJ, Sarkar H, Mindermann T, Reisch R: Keyhole supracerebellar transtentorial transcollateral sulcus approach to the lateral ventricle. *Neurosurgery* 73 (2 Suppl Operative):E295–E301, 2013

3)

Saito R, Kumabe T, Sonoda Y, Kanamori M, Mugikura S, Takahashi S, Tominaga T. Infarction of the lateral posterior choroidal artery territory after manipulation of the choroid plexus at the atrium: causal association with subependymal artery injury. *J Neurosurg*. 2013 Jul;119(1):158-63. doi: 10.3171/2013.2.JNS121221. Epub 2013 Mar 29. PubMed PMID: 23540272.

4) , 6)

Yasargil MG, Abdulrauf SI. Surgery of intraventricular tumors. *Neurosurgery*. 2008;62(6 suppl 3):1029-1040.

5)

Izci Y, Seçkin H, Ates O, Bas,kaya MK. Supracerebellar transtentorial transcollateral sulcus approach to the atrium of the lateral ventricle: microsurgical anatomy and surgical technique in cadaveric dissections. *Surg Neurol*. 2009;72(5):509-514.

7)

Kawashima M, Li X, Rhoton AL Jr, Ulm AJ, Oka H, Fujii K. Surgical approaches to the atrium of the lateral ventricle: microsurgical anatomy. *Surg Neurol*. 2006 May;65(5):436-45. PubMed PMID: 16630901.

8)

Peter PS, Joseph MP. Tumors of the lateral ventricle. *Neurosurg Q*. 1997;7(4): 286-300.

9)

Jeelani Y, Gokoglu A, Anor T, Al-Mefty O, Cohen AR. Transtentorial transcollateral sulcus approach to the ventricular atrium: an endoscope-assisted anatomical study. *J Neurosurg*. 2016 Jun 24:1-7. [Epub ahead of print] PubMed PMID: 27341050.

10)

Andoh T, Shinoda J, Miwa Y, Hirata T, Sakai N, Yamada H, Shimokawa K. Tumors at the trigone of the lateral ventricle—clinical analysis of eight cases. *Neurol Med Chir (Tokyo)*. 1990 Sep;30(9):676-84. PubMed PMID: 1708458.

11)

Cheng CY, Shetty R, Sekhar LN. Microsurgical Resection of a Large Intraventricular Trigonal Tumor: 3-Dimensional Operative Video. *Oper Neurosurg (Hagerstown)*. 2018 Mar 30. doi: 10.1093/ons/opy068. [Epub ahead of print] PubMed PMID: 29618124.

From:

<https://neurosurgerywiki.com/wiki/> - **Neurosurgery Wiki**

Permanent link:

https://neurosurgerywiki.com/wiki/doku.php?id=trigone_tumor

Last update: **2024/06/07 02:52**

