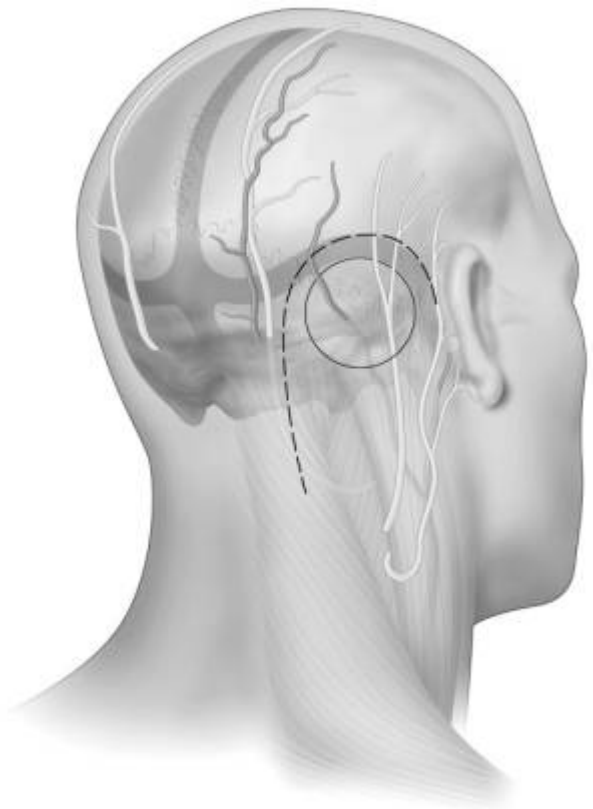


Retrosigmoid approach



- [Prognostic Factors for Facial Nerve Outcome after Vestibular Schwannoma Surgery: A 12-Year Multicentric Retrospective Study](#)
- [Perspectives on Minimum Neurotology Fellowship Case Numbers: A Survey of American Neurotology Society Members](#)
- [Congress of Neurological Surgeons Systematic Review and Evidence-Based Guideline on Surgical Resection for the Treatment of Patients With Vestibular Schwannomas: Update](#)
- [The Influence of Endoscopic Techniques on the Exposure Range of the Petroclival Region and the Protection of the Abducens Nerve in the Retrosigmoid Approach: An Anatomical Comparative Study](#)
- [Endoscopic Resection of Right Petrous Meningioma Causing Trigeminal Neuralgia: "The Double Crush" Phenomenon](#)
- ["Salvage surgery for vestibular schwannomas after failed stereotactic radiosurgery or radiation: A systematic review and meta-analysis"](#)
- [Endoscope-Assisted Microsurgical Removal of Trigeminal Schwannomas](#)
- [Combined Microscopic-Endoscopic Retrosigmoid Approach for a Cerebellopontine Angle Epidermoid Cyst With Supratentorial Extension: Nuances for Maximizing Resection With Cranial Nerve Preservation: 2-Dimensional Operative Video](#)

The unilateral [suboccipital approach](#) was popularized by Woolsey (1903) and with great contributions by [Fedor Krause](#) (1905).

After several refinements and modifications through different dedicated neurosurgeons (Fish, House

and Seiffert, Dandy's suboccipital approach (1917) with an ipsilateral suboccipital flap evolved to the [retrosigmoid transmeatal approach](#).

The use of the retrosigmoid approach has expanded by several modifications, including the [suprameatal](#), [transmeatal](#), [suprajugular](#), and [inframeatal](#) extensions. Intradural temporal bone [drilling](#) without damaging vital structures inside or beside the bone, such as the [internal carotid artery](#) and [jugular bulb](#), is a key step for these extensions.

see [Retrosigmoid transmeatal approach](#).

see [Retrosigmoid intradural inframeatal approach](#).

Incisions

Although a number of [scalp incisions](#) and [flaps](#) for the [retromastoid approach](#) have been previously described and most commonly employed, these incisions and flaps each have their own advantages and limitations ¹⁾

Linear incision

The linear [incision](#) and its variations have been the most commonly employed methods due to their simplicity and versatility. The linear incision may be simply extended superiorly or inferiorly, if necessary, to tailor suboccipital bony removal and expose the junction of the transverse sinus and sigmoid dural sinuses.

This incision is usually placed just medial to the mastoid groove.

Although easy to execute, a linear retromastoid approach inherently limits the surgical area. The resultant “bunching” of the skin and deep muscles, upon placement of the retractor parallel to the line of the incision, increases the working distance between the surgeon and the cerebellopontine angle

The incision is usually 8 to 10 cm long and is made one fingerbreadth medial to the mastoid process and [digastric groove](#).

The linear incision requires dissection of the posterior neck muscles, including the sternocleidomastoid muscle, and this muscle dissection, often leads to an increased postoperative discomfort and long-term suboccipital headaches due to scarring and muscle fibrosis. The occipital artery and occipital nerves (neurovascular bundle) may be easily sacrificed in this incision technique, further increasing the risk of postoperative painful neuroma formation.

The incision extends from a line just above the top of the pinna of the ear to a point just below the mastoid tip. Care in splitting the muscle at the inferior end is important in avoiding an ectatic vertebral artery. For very large lesions, the superior end of the incision can be extended medially to a point 2 cm above theinion and curved toward the midline (inverted hockey stick)

Once the linear retromastoid incision is cleared down to the bone, it can usually be held open by one or two curved cerebellar retractors.

C-shaped incision

This incision has become popular among skull-base surgeons, partly due to its associated multilayer closure that may lead to a potential decreased risk of incisional postoperative cerebrospinal fluid (CSF) leak. The “C-shaped” skin incision is based over the pinna, and the skin flap and muscle flap are dissected in separate layers and reflected laterally and inferiorly, respectively. The advantages of this incision include the fact that the myocutaneous flap will not interfere with the working space of the surgeon as it does in the case of the linear incision. The disadvantages include a more elaborate dissection required through the subcutaneous tissues and muscle layers. The lower part of the incision places the neurovascular bundle at a significant risk. The two-layered closure is more time consuming as well.

Curvilinear incision

see [Curved retromastoid incision](#)

The incision techniques described above can be reliably compared only in a randomized controlled trial requiring a large number of patients to provide enough statistical power to allow for a meaningful comparison across the three groups. Such a trial is unlikely to be performed; nonetheless, the retrospective nature of this analysis is a major limitation.

Craniotomy

see [Retrosigmoid craniotomy](#).

Complications

A combination of image-guidance and micro-Doppler enhances the accuracy in localizing the margins of the transverse and [sigmoid sinuses](#) in the [retrosigmoid approach](#), thus preventing inadvertent injury. The method could potentially be applied during other craniotomies involving the exposure of a venous sinus ²⁾.

The cause of postoperative headaches after retromastoid surgery, especially for patients who undergo resection of their vestibular schwannoma through this approach, is unknown, but scarring between the muscle and dura is implicated ³⁾

Indications

[Retrosigmoid approach indications](#).

Videos

<html><iframe width="420" height="315" src="https://www.youtube.com/embed/9vMydlfXDB4"

frameborder="0" allowfullscreen></iframe></html>

Case series

Ten patients with primary trigeminal neuralgia and 20 patients with hemifacial spasm (test group) were treated using retrosigmoid approach (RA) for microvascular decompression. Preoperative head magnetic resonance angiography and temporal bone computed tomography were performed and the images registered using SPM12 and fused with MRlcron to determine the relationship between mastoid air cells (MACs) and sigmoid sinuses. An O-arm was used for navigation, and the transverse sinus-sigmoid sinus was projected under a microscope to guide RA. A control group comprised 139 patients who had the same surgical procedure as the test group but without image processing or intraoperative navigation.

The relationship between mastoid air cells (MACs) and the ipsilateral sigmoid sinus was classified as follows: I, MACs did not exceed the lateral edge of the ipsilateral sigmoid sinus (10/60); II, MACs exceeded the ipsilateral lateral edge of the sigmoid sinus but did not exceed the medial edge (42/60); and III, MACs exceeded the medial edge of the ipsilateral sigmoid sinus (8/60). Test and control groups showed significant differences in the incidences of opening MACs ($P = 0.003$). There was no Cerebrospinal fluid fistula or scalp and intracranial infection at follow-up.

Image processing and intraoperative microscopic navigation can avoid unnecessarily opening MACs and might reduce postoperative cerebrospinal leakage and scalp infection after RA craniotomy ⁴.

2013

Consecutive 89 patients with untreated unilateral sporadic vestibular schwannoma undergoing tumor resection via a retrosigmoid approach during 2008-2010 were prospectively analysed. Endoscopy-assisted microsurgical (EA-MS) removal was performed in 39 cases (Grade 1: 2, Grade 2: 5, Grade 3: 9, Grade 4: 22, Grade 5: 1) and microsurgical (MS) removal was performed in 50 cases (Grade 1: 1, Grade 2: 3, Grade 3: 9, Grade 4: 34, Grade 5: 3). Minimally invasive approach with craniotomy ≤ 2.5 cm was employed for small tumors (Grade 1 and 2) in the EA-MS group. Endoscopic technique was used for monitoring of neuro-vascular anatomy in CPA, during dissection of the meatal portion of tumors, assessment of radicality and for identification of potential pathways for Cerebrospinal fluid fistula formation. All cases in MS group were deemed as radically removed. In the EA-MS group, residual tumor tissue in the fundus of internal auditory canal not observable with microscope was identified with endoscope in four cases. Such cases were radicalized. Tumor recurrence was not observed during the follow-up in EA-MS group. There is a suspicious intrameatal tumor recurrence on the repeated MRI scan in one patient in the MS group. Neither mortality nor infection was observed. The most common complication was pseudomeningocele (EA-MS 20 cases; MS 23). It was managed with aspiration with or without tissue-gluing in all cases without the need for any surgical revision. Adjunctive use of endoscope in the EA-MS group identified potential pathways for Cerebrospinal fluid fistula formation, which was not observable with the microscope in five patients. Improved cochlear nerve (EA-MS: 22, MS: 14; $p = 0.012$), brainstem auditory evoked potentials (EA-MS: 3 of 8, MS: 0 of 4) and hearing (EA-MS: 14 of 36, MS: 4 of 45; $p = 0.001$) preservation were observed in EA-MS group. Despite the trend for better useful hearing (Gardner-Robertson class 1 and 2) preservation (EA-MS: 8 of 26, MS: 1 of 16) there were no significant differences in the postoperative hearing handicap inventory in both groups. There were no differences in the postoperative tinnitus in both groups. Better facial nerve preservation (EA-MS: 39, MS: 44; $p = 0.027$) and excellent-very good (House-

Brackmann 1 or 2) facial nerve function (EA-MS: 31, MS: 29; $p = 0.035$) were observed in EA-MS group. Postoperative compensation of vestibular lesion, symptoms typical for VS, patients assessed by dizziness handicap inventory, facial disability index were comparable in both studied groups. Adjunctive use of endoscope during the VS surgery due to its magnification and illumination enable superior view in the operative field. It is valuable for assessment of radicality of resection in the region of internal auditory meatus. Improved information about critical structures and tumor itself helps the surgeon to preserve facial nerve and in selected cases also hearing. These techniques can help to decrease incidence of postoperative complications ⁵⁾.

Books

Functional Surgery of Cerebellopontine Angle by Minimally Invasive Retrosigmoid Approach

¹⁾

Kemp WJ, Cohen-Gadol AA. A review of skin incisions and scalp flaps for the retromastoid approach and description of an alternative technique. *Surg Neurol Int.* 2011;2:143. doi: 10.4103/2152-7806.85984. Epub 2011 Oct 12. PubMed PMID: 22059138; PubMed Central PMCID: PMC3205510.

²⁾

Baghdasaryan D, Albrecht M, Shahnazaryan M, Rosahl S. Real-time ultrasound Doppler enhances precision in image-guided approaches to the cerebello-pontine angle. *World Neurosurg.* 2017 Aug 10. pii: S1878-8750(17)31300-1. doi: 10.1016/j.wneu.2017.08.003. [Epub ahead of print] PubMed PMID: 28804044.

³⁾

Mosek AC, Dodick DW, Ebersold MJ, Swanson JW. Headache after resection of acoustic neuroma. *Headache.* 1999;39:89-94.

⁴⁾

Lin J, Zhang Y, Peng R, Ji X, Luo G, Luo W, Wang M, Zhu M, Sun X, Zhang Y. Preoperative Imaging and Microscopic Navigation During Surgery Can Avoid Unnecessarily Opening the Mastoid Air Cells Through Craniotomy Using the Retrosigmoid Approach. *World Neurosurg.* 2019 Jan;121:e15-e21. doi: 10.1016/j.wneu.2018.08.181. Epub 2018 Sep 3. PubMed PMID: 30189308.

⁵⁾

Chovanec M, Zvěřina E, Profant O, Skřivan J, Cakrt O, Lisý J, Betka J. Impact of video-endoscopy on the results of retrosigmoid-transmeatal microsurgery of vestibular schwannoma: prospective study. *Eur Arch Otorhinolaryngol.* 2013 Mar;270(4):1277-84. doi: 10.1007/s00405-012-2112-6. Epub 2012 Aug 4. PubMed PMID: 23010789.

From:

<https://neurosurgerywiki.com/wiki/> - **Neurosurgery Wiki**

Permanent link:

https://neurosurgerywiki.com/wiki/doku.php?id=retrosigmoid_approach

Last update: **2024/06/07 02:54**

