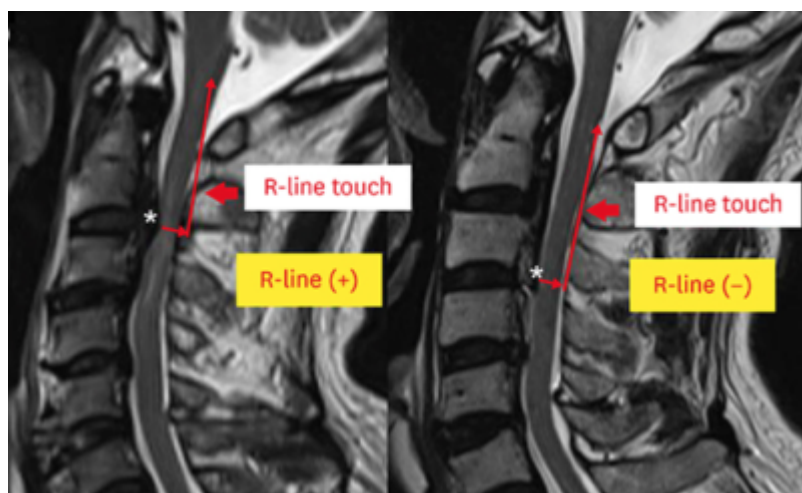


R-Line

Moon et al. developed a new [index](#) to determine the degree of [decompression](#) in [cervical ossification of the posterior longitudinal ligament](#)-the [rostral line](#) (R-line).

The R-line was defined as a line drawn through the posterior spinal canal parallel to the line connecting the center points of the [C2](#) and [C3 vertebral body](#) at the level of maximum [spinal cord compression](#)



If the R-line touches the upper half of the posterior [C2 lamina](#), total [C2 laminectomy](#) is necessary (R-line positive). In the R-line positive group, postoperative cord compression-only through C2 [undercutting](#) results in neurologic deterioration due to incomplete decompression.

A total of 79 consecutive patients who underwent posterior decompression of cervical OPLL were included in this study. Mean age at the time of operation, the C2-C7 [cervical lordotic angle](#) and OPLL thickness at the most stenotic level of the spinal canal, and preoperative/postoperative Japanese Orthopedic Association score was checked in these group. They compared the correspondence between the degree of C2 lamina decompression using the R-line and the actual degree of decompression.

In all patients, the R-line touched the upper half of the C2 lamina on preoperative magnetic resonance imaging (MRI). The C2-C3 local segment lordotic angle and maximal degree of spinal cord compression by OPLL were independently correlated to postoperative C2 cord shifting. This result indicates that the R-line is a valid indicator to determine the degree of C2 lamina decompression in OPLL extending to the C2 level.

The results showed that [undercutting](#) the [C2 lamina](#) can result in incomplete spinal cord decompression and poor clinical outcome if the R-line touches the upper half of the C2 lamina on preoperative MRI ¹⁾.

Lee et al. sought to evaluate the usefulness of the [rostral line](#) (R-line) as a new [index](#) for determining the degree of [C2 lamina decompression](#) in the context of [ossification of the posterior longitudinal](#)

ligament (OPLL) extending to the C2 level.

The R-line was devised based on the mechanism by which the cord is shifted backward following cervical posterior decompression. According to their R-line status, 36 patients with cervical OPLL extending to the C2 level were divided into two groups of R-line (+) and R-line (-) cases, where the R-line touched the upper half of the posterior C2 lamina in the R-line (+) group and the inferior half of the posterior C2 lamina in the R-line (-) group, respectively.

Eighteen patients were classified as R-line (+) and 18 patients were classified as R-line (-). Total laminectomy of the C2 lamina was more common in the R-line (+) group, while dome-shape C2 laminectomy was more common in the R-line (-) group. All patients requiring reoperation were included in the R-line (+) group. Only the operation type showed a statistically significant difference according to the need for reoperation in the R-line (+) group; specifically, all patients who underwent reoperation in the R-line (+) group had dome-shape C2 laminectomy. It was determined that the risk factor for reoperation in the R-line (+) group was a history of dome-shape C2 laminectomy.

If the R-line touches the upper half of the posterior C2 lamina, total decompression of the C2 lamina should be performed ²⁾.

References

¹⁾

Moon EJ, Lee BJ, Lee S, Jeon SR, Roh SW, Park JH. The R-line: A New Imaging Index for Decision Making Regarding C2 Lamina Decompression in Cervical Ossification of the Posterior Longitudinal Ligament. Korean J Neurotrauma. 2020 Apr 13;16(1):60-66. doi: 10.13004/kjnt.2020.16.e7. PMID: 32395452; PMCID: PMC7192802.

²⁾

Lee BJ, Lee S, Jeon SR, Roh SW, Park JH. A New Indicator Predicting the Degree of Cord Shift After Posterior Decompression of Cervical Ossification of the Posterior Longitudinal Ligament Extended to the C2 Level and Its Clinical Usefulness. Turk Neurosurg. 2020 Oct 16. doi: 10.5137/1019-5149.JTN.31668-20.1. Epub ahead of print. PMID: 33624283.

From:

<https://neurosurgerywiki.com/wiki/> - **Neurosurgery Wiki**

Permanent link:

<https://neurosurgerywiki.com/wiki/doku.php?id=r-line>

Last update: **2025/04/29 20:27**

