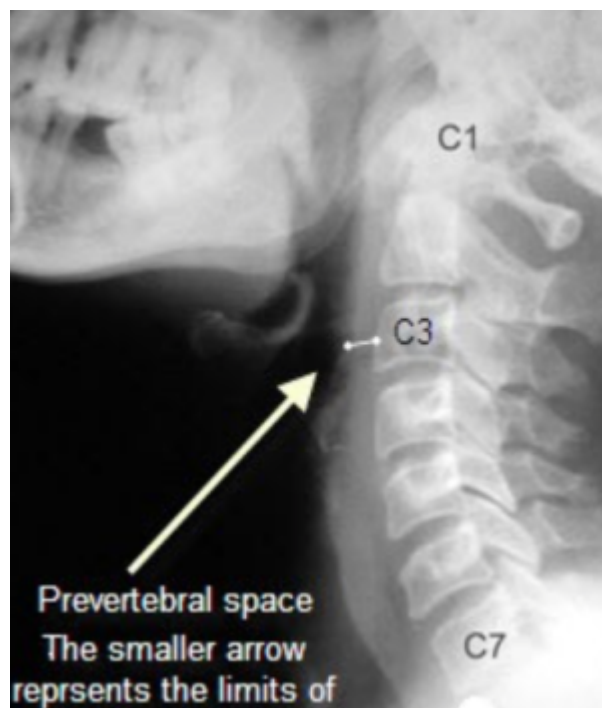


Prevertebral space

The prevertebral space is a space in the neck.



On one side it is bounded by the prevertebral fascia.

On the other side, some sources define it as bounded by the vertebral bodies, and others define it as bounded by the longus colli.

It includes the prevertebral muscles (longus colli and longus capitis), vertebral artery, vertebral vein, scalene muscles, phrenic nerve and part of the brachial plexus.

Prevertebral Space Abscess

[Prevertebral Space Abscess](#)

From:

<https://neurosurgerywiki.com/wiki/> - **Neurosurgery Wiki**

Permanent link:

https://neurosurgerywiki.com/wiki/doku.php?id=prevertebral_space

Last update: **2025/02/25 11:55**

