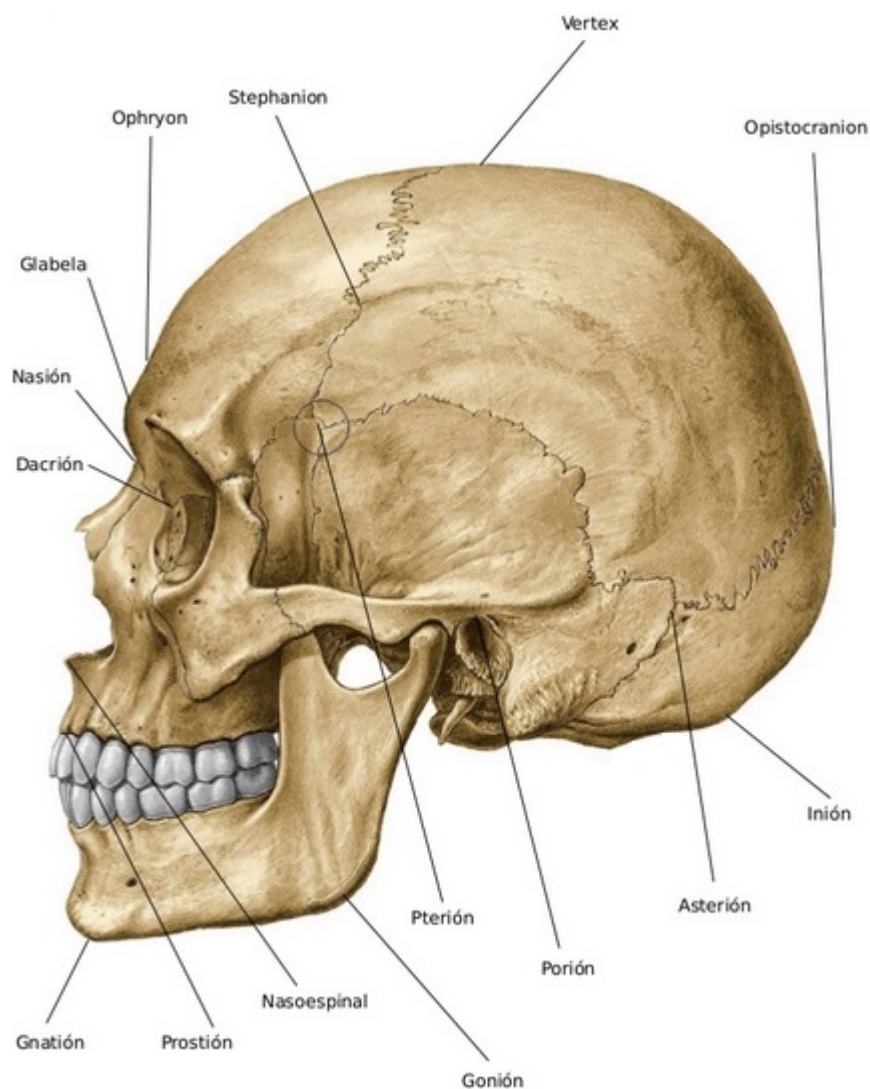


# Porion



The [Frankfurt plane](#) or Frankfort plane (both spellings are widely used, and the term is entered as Frankfort horizontal plane in several medical dictionaries, although Frankfurt is the modern standard spelling of the city it is named for) was established at the World Congress on Anthropology in Frankfurt am Main, Germany in 1884, and decreed as the anatomical position of the human skull. It was decided that a plane passing through the inferior margin of the left [orbit](#) (the point called the left orbitale) and the upper margin of each ear canal or external auditory meatus, a point called the [porion](#), was most nearly parallel to the surface of the earth, and also close to the position the head is normally carried in the living subject.

From:

<https://neurosurgerywiki.com/wiki/> - **Neurosurgery Wiki**

Permanent link:

<https://neurosurgerywiki.com/wiki/doku.php?id=porion>

Last update: **2024/06/07 02:51**



