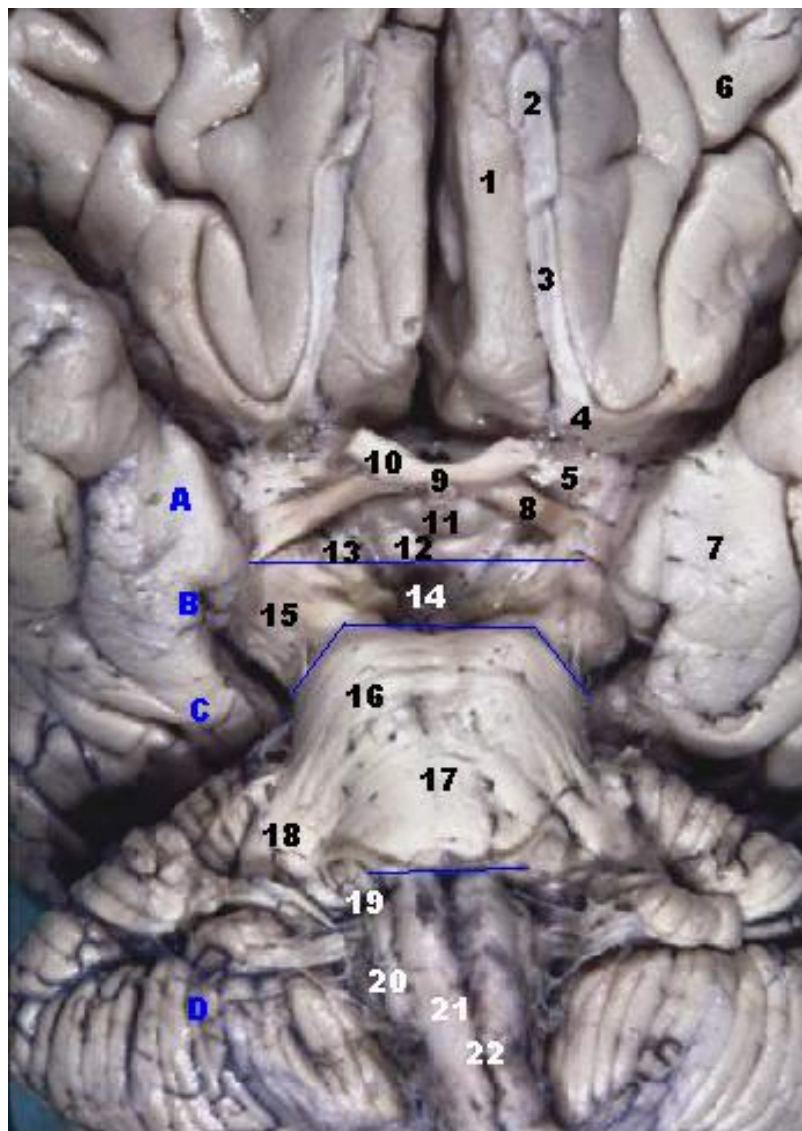


## Parahippocampal gyrus

The parahippocampal **gyrus** (Syn. hippocampal gyrus) is a **grey matter** cortical region of the brain ☐ that surrounds the **hippocampus** and is part of the **limbic system**. This region plays an important role in memory encoding and retrieval.



Number 7



Operations on tumors of the posteromedial temporal (PMT) region, that is, on those arising from the posterior parahippocampal gyrus, are challenging to perform because of the deep-seated location of these tumors between critical cisternal neurovascular structures and the adjacent temporal and occipital cortices.

A certain number of patients suffer significant decline in **verbal memory** after **hippocampectomy**. To prevent this disabling complication, a reliable test for predicting postoperative memory decline is greatly desired. Therefore, Tani et al., assessed the value of electrical stimulation of the **parahippocampal gyrus** (PHG) as a provocation test of verbal memory decline after hippocampectomy

on the dominant side.

Eleven right-handed, Japanese-speaking patients with medically intractable left [temporal lobe epilepsy](#) (TLE) participated in the study. Before surgery, they underwent provocative testing via electrical stimulation of the left PHG during a verbal encoding task. Their pre- and posthippocampectomy memory function was evaluated according to the Wechsler Memory Scale-Revised (WMS-R) and/or Mini-Mental State Examination (MMSE) before and 6 months after surgery. The relationship between postsurgical memory decline and results of the provocative test was evaluated.

Left hippocampectomy was performed in 7 of the 11 patients. In 3 patients with a positive provocative recognition test, verbal memory function, as assessed by the WMS-R, decreased after hippocampectomy, whereas in 4 patients with a negative provocative recognition test, verbal memory function, as assessed by the WMS-R or MMSE, was preserved.

Results of the present study suggest that electrical stimulation of the PHG is a reliable provocative test to predict posthippocampectomy verbal memory decline <sup>1)</sup>.

<sup>1)</sup>

Tani N, Kishima H, Khoo HM, Yanagisawa T, Oshino S, Maruo T, Hosomi K, Hirata M, Kazui H, Nomura KT, Aly MM, Kato A, Yoshimine T. Electrical stimulation of the parahippocampal gyrus for prediction of posthippocampectomy verbal memory decline. J Neurosurg. 2016 Nov;125(5):1053-1060. PubMed PMID: 26771851.

From:

<https://neurosurgerywiki.com/wiki/> - **Neurosurgery Wiki**

Permanent link:

[https://neurosurgerywiki.com/wiki/doku.php?id=parahippocampal\\_gyrus](https://neurosurgerywiki.com/wiki/doku.php?id=parahippocampal_gyrus)

Last update: **2024/06/07 02:55**

