Paracentral lobule

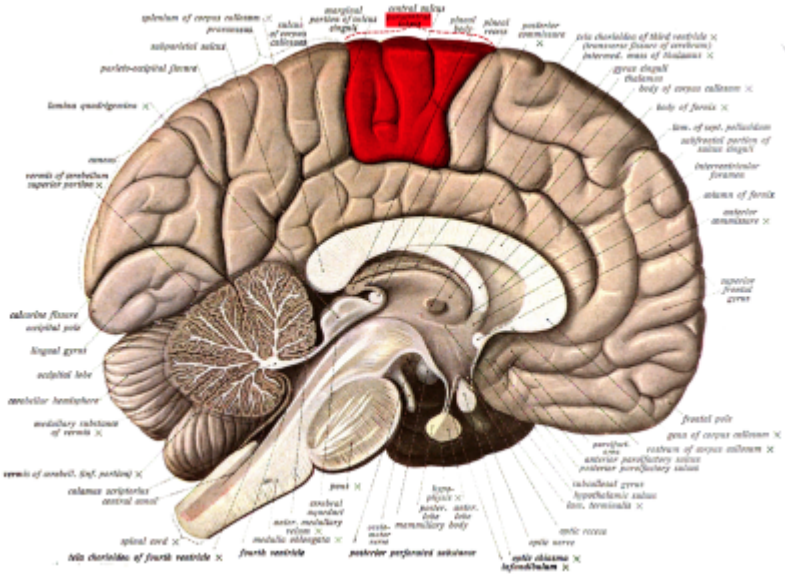

Paracentral lobule is on the medial surface of the hemisphere and is the continuation of the precentral gyrus and postcentral gyrus.

Blood supply

The paracentral lobule is supplied blood by the anterior cerebral artery. The paracentral lobule controls motor and sensory innervations of the contralateral lower extremity. It is also responsible for control of defectation and urination.

It includes portions of the frontal and parietal lobes:

The anterior portion of the paracentral lobule is part of the frontal lobe and is often referred to as the supplementary motor area. The posterior portion is considered part of the parietal lobe and deals with somatosensory of the distal limbs. While the boundary between the lobes, the central sulcus, is easy to locate on the lateral surface of the cerebral hemispheres, this boundary is often discerned in a cytoarchetectonic manner in cases where the central sulcus is not visible on the medial surface.

---

see also Central lobe tumor

From:
https://neurosurgerywiki.com/wiki/ - **Neurosurgery Wiki**

Permanent link:
https://neurosurgerywiki.com/wiki/doku.php?id=paracentral_lobule

Last update: **2024/06/07 02:54**