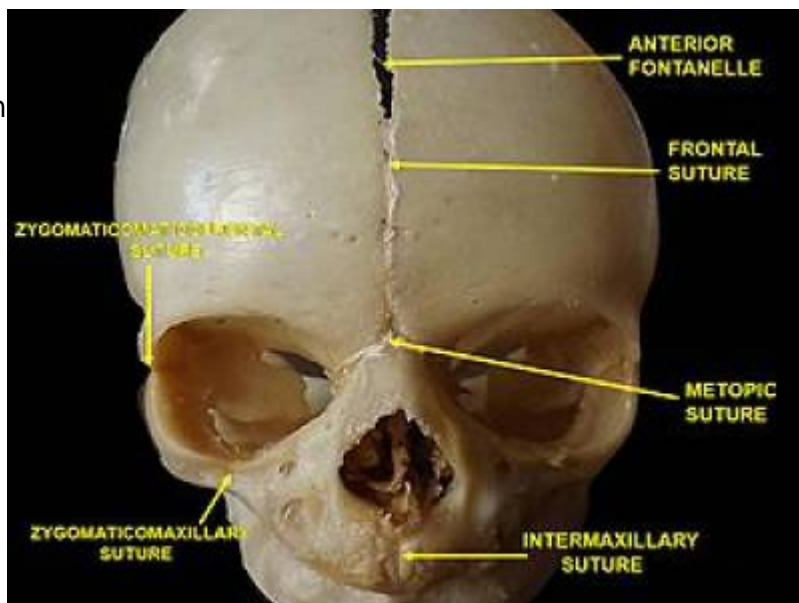


Metopic suture

The metopic suture (also known as the median frontal suture) is a type of calvarial suture. It is often associated with frontal sinus agenesis or hypoplasia.



This suture runs through the midline across the frontal bone from the nasion to the bregma, although it may often be incomplete. It usually fuses by around 9 months of age 1-4.

A premature fusion of the suture is termed metopic synostosis (type of craniosynostosis) with can then result in trigonocephaly.

The metopic suture is usually obliterated by about 7 years of age, but in rare cases it can persist 6 as an anatomical variant of little clinical significance but that it can be mistaken for frontal bone fracture.

Differential diagnosis

Frontal bone fracture

Metopic sutures have a characteristic midline position and demonstrate sutural interdigitations.

From:
<https://neurosurgerywiki.com/wiki/> - Neurosurgery Wiki

Permanent link:
https://neurosurgerywiki.com/wiki/doku.php?id=metopic_suture

Last update: 2024/06/07 02:57

