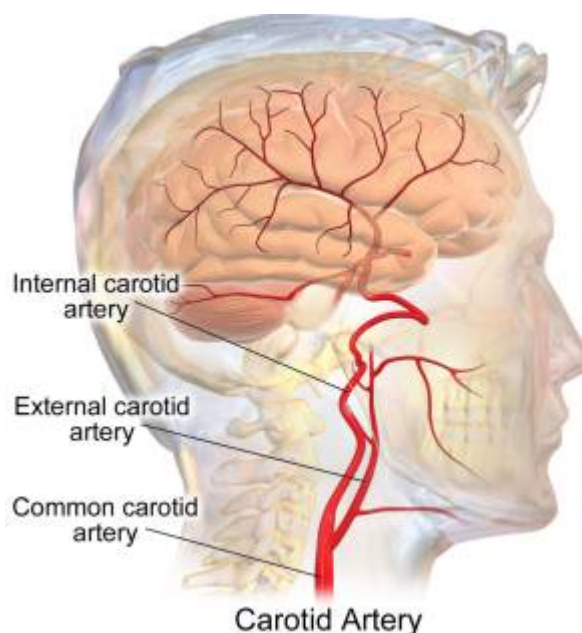


Internal carotid artery



The internal [carotid artery](#) is a major paired [artery](#), one on each side of the head and neck, in human anatomy. They arise from the [common carotid artery](#) where these bifurcate into the internal and [external carotid artery](#); the internal carotid artery supplies the brain, while the external carotid nourishes other portions of the head, such as face, scalp, skull, and meninges.

The internal carotid arteries supply blood to the anterior three-fifths of the cerebrum, except for parts of the temporal and occipital lobes.

Any decrease in the flow of blood through one of the internal carotid arteries brings about some impairment in the function of the frontal lobes. This impairment may result in numbness, weakness, or paralysis on the side of the body opposite to the obstruction of the artery.

Segments

see [Internal carotid artery segments](#).

Branches

The following are the branches of the internal carotid artery, listed by segment:

C1: Branches from the cervical portion - none.

C2: Branches from the petrous portion

[Caroticotympanic artery](#) or arteries

Artery of pterygoid canal (vidian artery)

C3: Branches from the lacerum portion - none

C4: Branches from the cavernous portion

The [meningohypophyseal trunk](#), also known as the posterior trunk, is a branch of the C4 segment of the [internal carotid artery](#).

C5: Branches from the clinoid portion - none

C6.

C7: Branches from the communicating portion

Posterior communicating artery

Anterior choroidal artery

Anterior cerebral artery (a terminal branch)

Middle cerebral artery (a terminal branch)

Anastomosis

Although anastomoses between the arterial branches arising from the internal carotid artery (ICA) can develop as collateral pathways between the bilateral ICAs in cases of dysgenesis of the ICA, anastomosis of the recurrent arteries branching from the first segment of the ophthalmic artery (OphA) has not been described. Herein, we report two cases of this rare anastomosis. In a 36-year-old man with left segmental dysgenesis of the ICA, an anastomosis between the bilateral ICAs developed around the sella turcica. In a 39-year-old woman with dysgenesis of the bilateral distal ICAs, an anastomosis between the superior hypophyseal trunk and bilateral ICAs was identified. The anastomoses in both cases were also supplied by recurrent arteries branching from the first segment of the OphAs. This is the first report describing recurrent arteries from the OphAs that form the anastomosis between bilateral ICAs ¹⁾.

Pathology

[Internal carotid artery aneurysm.](#)

[Internal carotid artery stenosis](#)

[Internal carotid artery hypoplasia.](#)

[Internal carotid artery injury.](#)

[Internal Carotid Artery Agenesis.](#)

¹⁾

Ando M, Maki Y, Hojo M, Hatano T. Rare anastomosis between the bilateral internal carotid arteries via the recurrent arteries branching from the first segment of the ophthalmic artery. *Neuroradiology*. 2022 Apr 27. doi: 10.1007/s00234-022-02965-2. Epub ahead of print. PMID: 35474401.

From:

<https://neurosurgerywiki.com/wiki/> - **Neurosurgery Wiki**

Permanent link:

https://neurosurgerywiki.com/wiki/doku.php?id=internal_carotid_artery

Last update: **2024/06/07 02:55**

