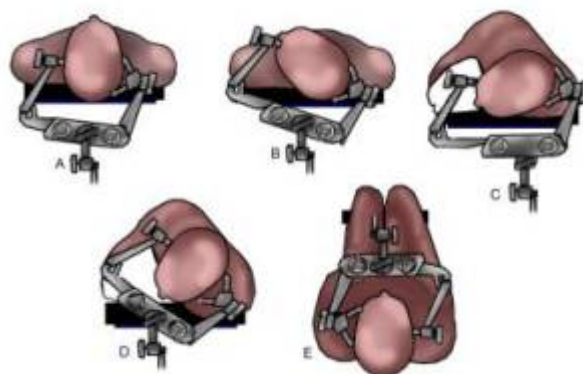


# Head fixation device complications in pediatric neurosurgery



Head Fixation in pediatric neurosurgery is associated with complications.

They are widely used among pediatric neurosurgeons in patients younger than 5 years old. Guidelines for their safe use are not well defined despite common use and experience of significant complications associated with such devices <sup>1)</sup>.

Variability in the thickness of the developing cranium necessitates age-specific considerations to reduce the risk of adverse events. To suggest possible guidelines for the use of cranial fixation pins in children, Berry et al. surveyed neurosurgeons treating pediatric patients regarding their experience with such devices.

An Institutional Review Board-approved, 30-item multiple choice survey was provided by electronic mail to 605 neurosurgeons treating pediatric patients. The survey included specific questions regarding their experience with cranial fixation pins with respect to age ranges of patients, selection of pin size, type of pin pressure applied, and complications encountered.

One hundred sixty-four (27%) responses were received. One hundred fifty-eight of the 164 (96%) neurosurgeons reported using cranial fixation pins in their pediatric practice. Forty-four of the 164 (27%) apply fixation pins in patients aged 1 to 2 years. Eighty-two (50%) apply pins in patients aged 2 to 3 years, and 89 (54%) apply pins in patients aged 3 to 4 years. For patients aged 2 to 5 years old, the majority of responders use between 10 and 40 pounds of pressure, whereas for those older than 5 years of age, most use between 30 and 40 pounds of pressure. After age 10, patients are treated as adults. Eighty-nine of the 164 (54%) responders reported complications directly related to the use of cranial fixation pins, including cranial fracture, epidural or subdural hematoma, scalp laceration, or cerebrospinal fluid leak. One hundred fifty-four of the 164 (94%) neurosurgeons responded that they are not aware of any standard guidelines for cranial fixation pin use in pediatric patients. Seven (4%) who stated that they were aware of guidelines did not describe where they obtained those guidelines.

Cranial fixation pins are widely used among pediatric neurosurgeons in patients younger than 5 years old. Guidelines for their safe use are not well defined despite common use and experience of significant complications associated with such devices. <sup>2)</sup>

Udayakumaran et al. applied a headband made of Plaster of Paris (POP) around the head and then applying the fixation pins of the fixation frame directly on to the POP.

They used this technique of head fixation successfully for infants with no complications <sup>3)</sup>.

---

Agrawal et al. described an extremely simple technique of head fixation for image-guided neurosurgery in young children in whom standard pin fixation cannot be used.

This involves positioning the head on a horseshoe headrest and using a 'U-drape' to fix the head to the headrest.

Over the last 5 years, this technique of head fixation (in conjunction with Stealthstation) has been used for various neurosurgical procedures in more than ten infants successfully <sup>4)</sup>.

---

Rubber plugs (usually used for antibiotic bottles) pierced by the skull pins are used to avoid intracranial penetration of the pins. The upper surface of the rubber plugs attached to the scalp contributes to support of the head. Four infants were successfully treated in a prone position with this technique <sup>5)</sup>.

---

Gupta adapted a standard Mayfield horseshoe headrest and cranial fixation system to allow simultaneous use of the headrest and three-point pin fixation. The system is compatible with most neuronavigational systems.

The combined horseshoe and pin system was used successfully in more than 30 patients ranging in age from 6 months to 14 years. No complications were encountered.

Rigid immobilization is achievable in the pediatric population, facilitating intracranial and frameless stereotaxy procedures <sup>6)</sup>.

## Case series

Five of 766 children (0.65%) undergoing craniotomies with pin fixation of the head had depressed skull fractures and/or epidural hematomas from the pin fixation. Age ranged from 2.6 to 7.5 years; all fractures were temporal and occurred during posterior fossa craniotomies <sup>7)</sup>.

---

Lee et al. examined complications over the past 6 years, and encountered 5 children with depressed skull fractures secondary to the application of a skull clamp fixation device. There were 3 boys and 2 girls with ages ranging from 3 to 8 years (mean 5.8 years). Two patients had brainstem gliomas, 2 patients had hypothalamic gliomas and 1 patient had a medulloblastoma. Four of the children

required separate cranial procedures for the exploration and elevation of the depressed fractures. There were no sequelae associated with the depressed fractures. We conclude that skull clamp fixation devices are safe, but should be used with caution in the pediatric patient. In addition, we present several modifications of existing skull clamps which may decrease the risk of depressed skull fractures <sup>8)</sup>.

## Case reports

An 11-year-old girl diagnosed with non-communicating hydrocephalus, caused by a posterior fossa tumor. During the surgery, complications were found in the form of acute epidural hematoma due to head fixation pins. So, the operation was stopped. An emergent CT scan was carried out and showed a bilateral skull fracture and a massive right-sided epidural hematoma. An emergency craniotomy for clot removal was performed and five days later, a second surgery was carried out uneventfully for the residual tumor. The patient fully recovered after the second surgery.

Complications due to the use of a pinhead fixation are easier to occur in pediatric patients because the bones are thinner and need a more careful strategy when pinning. With prompt identification of any complications and earlier treatment, a good outcome will be achieved.

Parenrengi et al. compared this case report with published literature in order to suggest a way to prevent this complication.

Skull fractures and associated epidural hematomas in pediatric patients need to be considered as possible complications of the pin-type head fixation application. The head fixation devices in pediatric need to be used with great caution and knowing the risk factors, safe technique for application and management of complications will prevent a worse outcome <sup>9)</sup>.

---

A 4-year-old girl who sustained a depressed skull fracture by penetration of a pin of the head holder. The fracture was noted at the end of the surgery performed for treatment of a cerebellar astrocytoma and was managed conservatively.

Several factors seem to be involved in the production of this complication as are faulty application of the pins, excessive pin pressure, skull thinning, young patient's age, and pathological conditions that evolve with long-standing raised intracranial pressure <sup>10)</sup>.

---

A 5-month-old girl with a growing lesion in the right thalamus and basal ganglia underwent stereotactic biopsy, which disclosed an anaplastic astrocytoma. To avoid insertion of the four stereotactic frame fixation pins through the infant's skin and into bone, the pins were advanced into the hollowed end of rubber tops obtained from Vacutainer blood sampling tubes. The pressure applied to the skin was diffused through the rubber onto a wide skin surface, obviating skin puncture or bone deformation. This technique provided firm head fixation, and target accuracy was confirmed on postoperative imaging. This technique is safe and should permit the use of conventional stereotactic techniques in young infants <sup>11)</sup>.

## References

1) 2)

Berry C, Sandberg DI, Hoh DJ, Krieger MD, McComb JG. Use of cranial fixation pins in pediatric neurosurgery. *Neurosurgery*. 2008 Apr;62(4):913-8; discussion 918-9. doi: 10.1227/01.neu.0000318177.95288.cb. PubMed PMID: 18496197.

3)

Udayakumaran S, Onyia CU. Customizable rigid head fixation for infants: technical note. *Childs Nerv Syst*. 2016 Jan;32(1):159-61. doi: 10.1007/s00381-015-2896-y. Epub 2015 Sep 4. PubMed PMID: 26337702.

4)

Agrawal D, Steinbok P. Simple technique of head fixation for image-guided neurosurgery in infants. *Childs Nerv Syst*. 2006 Nov;22(11):1473-4. Epub 2006 Sep 19. PubMed PMID: 17047964.

5)

Aoki N, Sakai T. Modified application of three-point skull clamp for infants. *Neurosurgery*. 1989 Oct;25(4):660-2. PubMed PMID: 2677825.

6)

Gupta N. A modification of the Mayfield horseshoe headrest allowing pin fixation and cranial immobilization in infants and young children. *Neurosurgery*. 2006 Feb;58(1 Suppl):ONS-E181; discussion ONS-E181. PubMed PMID: 16462615.

7)

Vitali AM, Steinbok P. Depressed skull fracture and epidural hematoma from head fixation with pins for craniotomy in children. *Childs Nerv Syst*. 2008 Aug;24(8):917-23; discussion 925. doi: 10.1007/s00381-008-0621-9. Epub 2008 Apr 4. PubMed PMID: 18389258.

8)

Lee M, Rezai AR, Chou J. Depressed skull fractures in children secondary to skull clamp fixation devices. *Pediatr Neurosurg*. 1994;21(3):174-7; discussion 178. PubMed PMID: 7803306.

9)

Parenrengi MA, Adhiatmadja F, Arifianto MR, Apriawan T, Fauzi AA, Servadei F. Bilateral skull fracture with massive epidural hematoma secondary to pin-type head fixation in a pediatric patient: Case report and review of the literature. *Int J Surg Case Rep*. 2019 Aug 13;62:43-49. doi: 10.1016/j.ijscr.2019.07.079. [Epub ahead of print] PubMed PMID: 31445499.

10)

Martínez-Lage JF, Almagro MJ, Serrano C, Mena L. Depressed skull fracture by a three-pin head holder: a case illustration. *Childs Nerv Syst*. 2011 Jan;27(1):163-5. doi: 10.1007/s00381-010-1213-z. Epub 2010 Jun 24. PubMed PMID: 20574740.

11)

Kondziolka D, Adelson PD. Technique of stereotactic biopsy in a 5-month-old child. *Childs Nerv Syst*. 1996 Oct;12(10):615-8. PubMed PMID: 8934022.

From: <https://neurosurgerywiki.com/wiki/> - **Neurosurgery Wiki**

Permanent link: [https://neurosurgerywiki.com/wiki/doku.php?id=head\\_fixation\\_device\\_complications\\_in\\_pediatric\\_neurosurgery](https://neurosurgerywiki.com/wiki/doku.php?id=head_fixation_device_complications_in_pediatric_neurosurgery)

Last update: **2024/06/07 02:53**

