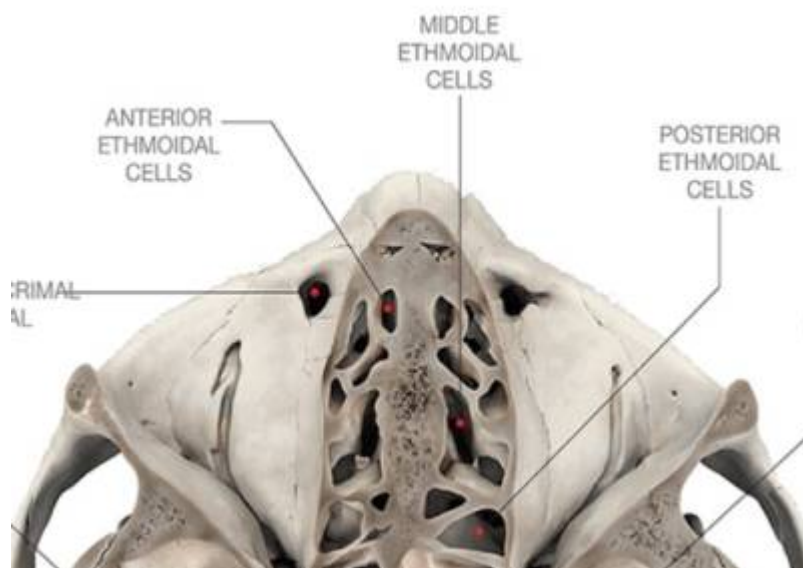


# Ethmoidal air cells



The ethmoidal air cells, also known less commonly as the [ethmoidal sinuses](#), form one of the four pairs of [paranasal sinuses](#). They are located within the single, midline [ethmoid bone](#).

They are variable in both size and number of small cavities in the lateral mass of each of the ethmoid bones and cannot be palpated during an extraoral examination.

They are divided into the anterior, middle, and posterior groups. The ethmoidal air cells consist of numerous thin-walled cavities situated in the ethmoidal labyrinth and are completed by the frontal, maxilla, lacrimal, sphenoidal, and palatine bones. They lie between the upper parts of the nasal cavities and the orbits and are separated from these cavities by thin bony laminae.

From:

<https://neurosurgerywiki.com/wiki/> - **Neurosurgery Wiki**

Permanent link:

[https://neurosurgerywiki.com/wiki/doku.php?id=ethmoidal\\_air\\_cells](https://neurosurgerywiki.com/wiki/doku.php?id=ethmoidal_air_cells)

Last update: **2024/06/07 02:53**

