

Encephalocele

Encephaloceles are [congenital disorders](#) characterized by externalization of the [meninges](#) and/or [brain tissue](#) through a congenital [skull bone defect](#).

They arise from inadequate closure of [neural tube](#) during the first month of embryonic development.

Encephaloceles cause a groove down the middle of the skull, or between the forehead and nose, or on the back side of the skull. The severity of encephalocele varies, depending on its location.

They may contain meninges (meningocele), brain matter and meninges (meningoencephalocele) or they may communicate with the ventricles (meningoencephalocystocele) ¹⁾.

Epidemiology

In developed countries, this malformation is rare but in developing countries, this pathology remains important.

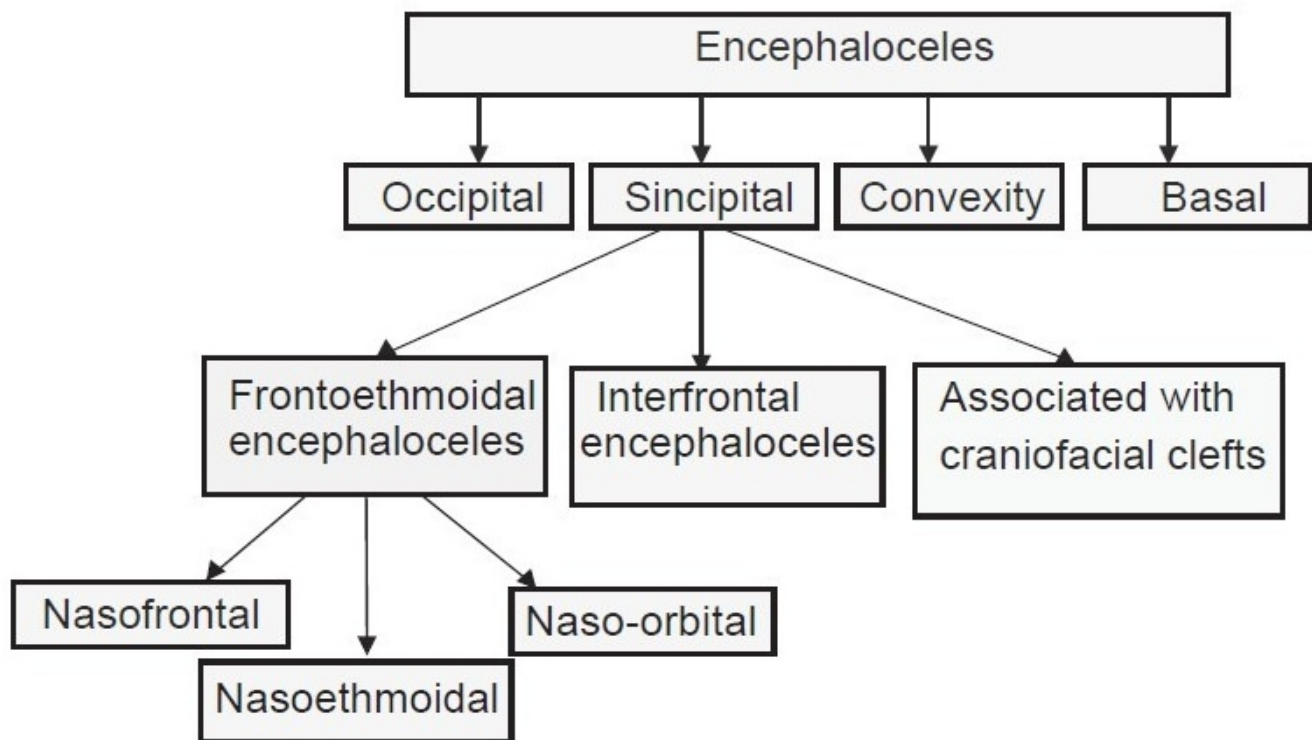
[Nasoethmoidal encephalocele](#) is the most common and naso-orbital subtype is least common

Etiology

Despite many theories, the cause of congenital cephalocele is not known.

These defects are caused by failure of the neural tube to close completely during fetal development.

Classification



2)

see [Basal encephalocele](#).

They are also classified according to their contents and location.

see [meningoencephalocele](#).

see [Anterior encephalocele](#).

see [temporal bone encephalocele](#).

see [Small temporal pole encephalocele](#)

Sincipital meningoencephaloceles (fronto-ethmoidal meningoencephaloceles).

Basal encephalocele accounts only 1.5% of all encephaloceles. But Sphenorbital encephalocele is the rarest cause of herniation of brain into orbit leading to pulsatile exophthalmos.

Trivedi et al. present a case of sphenorbital encephalocele in a 16 yrs old girl successfully managed by orbitcranioplasty by partial thickness autologous calvarial bone graft.

[Tegmen tympani defect....](#)

Diagnosis

Preoperative work-up includes 3-dimensional computed tomography scan of the facial skeleton.

Treatment

Encephalocele treatment.

Complications

After surgery, mental failure and [hydrocephalus](#) can occur impairing the prognosis.

Case series

In a [retrospective study](#) of the association of [hydrocephalus](#) with [neural tube defect](#) ([spina bifida](#) or [cephalocele](#)) managed over a period of 7 years at the Department of Neurosurgery, [University Hospital Yalgado Ouedraogo](#), thirty-eight cases were included. The mean age was 8.1 months, and the sex ratio was 0.81. There were 27 cases of spina bifida and 11 cases of [cephalocele](#) associated with [hydrocephalus](#). A cerebral [CT](#) scan was performed in all patients. In 30 cases, the operative management of these pathologies was performed at the same operative time. Eight cases were operated in 2 separate operative stages with a mean time of 30 days between the 2 operations. The course was favorable in 22 patients operated by the simultaneous approach and in 3 patients operated by the separate approach ($p = 0.07$).

Surgical management of the association of [hydrocephalus](#) with neural tube defect in 1 or 2 operative stages gave similar clinical results. However, the treatment in 1 surgical stage would considerably reduce the charges ³⁾.

2017

Data of all neonates with encephaloceles who presented to the Department of Neurosurgery, Universitätsmedizin Greifswald, Klinik und Poliklinik für Neurochirurgie, Germany and Department of Neurosurgery, Cairo University Kasr Alainy Faculty of Medicine, Cairo, Egypt from September 2012 to September 2014 were collected. Surgery was performed during the first 2 weeks of age. Encephaloceles with a maximal diameter > 10 cm were included in the study, and the clinical picture, surgical technique, pre- and postoperative imaging, and follow-up were analyzed. Results Nineteen cases were included in this study. The mean follow-up period was 7 months. Sixteen cases were occipital; three were frontal. In all patients the maximum diameter was > 10 cm. However, in four patients it was > 18 cm. Postoperative ventriculomegaly occurred in seven cases. Of these, four patients needed a permanent ventriculoperitoneal shunt implantation (21%). Wound dehiscence occurred in two patients who required secondary sutures with a favorable outcome. One patient died 2 weeks after the surgery due to a poor general condition and wound infection. Conclusion Early surgical excision provides effective treatment of huge encephaloceles. Overall, 21% of cases require cerebrospinal fluid (CSF) diversion afterward depending on associated anomalies. Despite their size, giant encephaloceles can have an excellent prognosis with no need for further treatment or CSF diversion ⁴⁾.

2016

A retrospective analysis of 32 occipital encephaloceles managed operatively at the Neurosurgery Department Clinics of the Faculty of Medicine, Adiyaman University [Turkey](#), was performed between 2011 and 2015.

Among the study population, 19 mothers had been exposed to TORCH infections ([toxoplasmosis](#), rubella, [cytomegalovirus](#), [herpes simplex virus](#)), 18 were in consanguineous marriages, and 3 had regular prenatal screening. Associated congenital anomalies were common. Eight infants required reoperation, and 9 died during follow-up.

The study identified key areas for prevention. Knowledge of the intracranial and associated anomalies can guide management. ⁵⁾

2015

A retrospective study was conducted from 2007 to 2013 on all cases of cephalocele supported in the department of neurosurgery of the Yalgado Ouédraogo University Teaching Hospital of [Ouagadougou](#). The malformations were supplemented by CT scan. All patients were operated. The surgical procedure in cephalocele of the convexity consisted of a direct approach. Sincipital cephalocele were operated by transcranial approach or combined approach associating transcranial and transnasal approaches.

Fifty patients were gathered during the 7-year period. There were 18 boys and 32 girls. The ages ranged from 1 day to 11 years. The cephalocele were located on the vault of the skull in 78%; the lesion was sincipital in 22%. The malformation was covered with normal skin in 92%; it was pediculated in 78%. CT scan allowed the classification of cases as meningo-encephalocele in 31 cases (62%) and meningocele in 18 cases (36%) and one pure encephalocele. The immediate postoperative course was uneventful in 42 cases (84%); 8 postoperative deaths were recorded. At medium and long term, 4 patients (8%) developed complications of psychomotor deficiency in 3 cases and hydrocephalus in 1 case. The main reasons for the poor prognosis were superinfection, hydrocephalus and/or other brain malformations ⁶⁾.

¹⁾

Suwanwela C, Suwanwela N. A morphological classification of sincipital encephalomeningocele. *J Neurosurg*. 1972 Feb;36(2):201-11. PubMed PMID: 5008734.

²⁾

Diebler C, Dulac O. Cephalocele: clinical and neuroradiological appearance. Associated cerebral malformations. *Neuroradiology*. 1983;25(4):199-216. PubMed PMID: 6633855.

³⁾

Zabsonre DS, Lankoande H, Zoungrana/Ouattara CFC, Thiombiano A, Ouedraogo S, Sanou A, Yameogo P, Kaboret-Douamba SJE, Kabre A. Association of Hydrocephalus with Neural Tube Defect: Our Experience with the Surgical Treatment in One or in Two Operative Stages (on Separate Days). *Pediatr Neurosurg*. 2018 Dec 5:1-5. doi: 10.1159/000494562. [Epub ahead of print] PubMed PMID: 30517948.

⁴⁾

Refaee EA, Refaat MI, Reda M. Incidence of Secondary Hydrocephalus after Excision of Huge Encephalocele in Neonates: Case Study. *J Neurol Surg A Cent Eur Neurosurg*. 2017 Feb 1. doi: 10.1055/s-0036-1597548. [Epub ahead of print] PubMed PMID: 28147383.

⁵⁾

Yucetas SC, Uçler N. A Retrospective Analysis of Neonatal Encephalocele Predisposing Factors and Outcomes. *Pediatr Neurosurg*. 2016 Dec 9. [Epub ahead of print] PubMed PMID: 27931021.

⁶⁾

Kabré A, Zabsonre DS, Sanou A, Bako Y. The cephaloceles: A clinical, epidemiological and therapeutic study of 50 cases. *Neurochirurgie*. 2015 Jun 26. pii: S0028-3770(15)00085-5. doi: 10.1016/j.neuchi.2015.03.011. [Epub ahead of print] PubMed PMID: 26123614.

From:

<https://neurosurgerywiki.com/wiki/> - **Neurosurgery Wiki**

Permanent link:

<https://neurosurgerywiki.com/wiki/doku.php?id=enkephalocele>

Last update: **2024/06/07 02:51**

