Central sulcus

- Evaluation of brain and neurophysiologic function in isolated congenital anosmia
- Keypoint localization and parameter measurement in ultrasound biomicroscopy anterior segment images based on deep learning
- Electrophysiological hemispheric asymmetries induced by parietal stimulation eliciting visual percepts
- Distinct mitotic dynamics and neuronal migration patterns between gyri and sulci in the ferret neocortex during cortical folding
- Micro-implant anchorage in adolescent orthodontics: a promising and advantageous option
- Dysregulation of the Immune System in Advanced Periimplantitis: Systemic Implications and Inflammatory Mechanisms-A Hematological and Immunological Study
- Single and paired TMS pulses engage spatially distinct corticomotor representations in human pericentral cortex
- Influence of Sulcus-Deepening Trochleoplasty on Patellofemoral Cartilage Integrity in Patients With Severe Trochlear Dysplasia at Short-term to Midterm Follow-up: A Case-Control Study

---

---

see Central sulcus region.

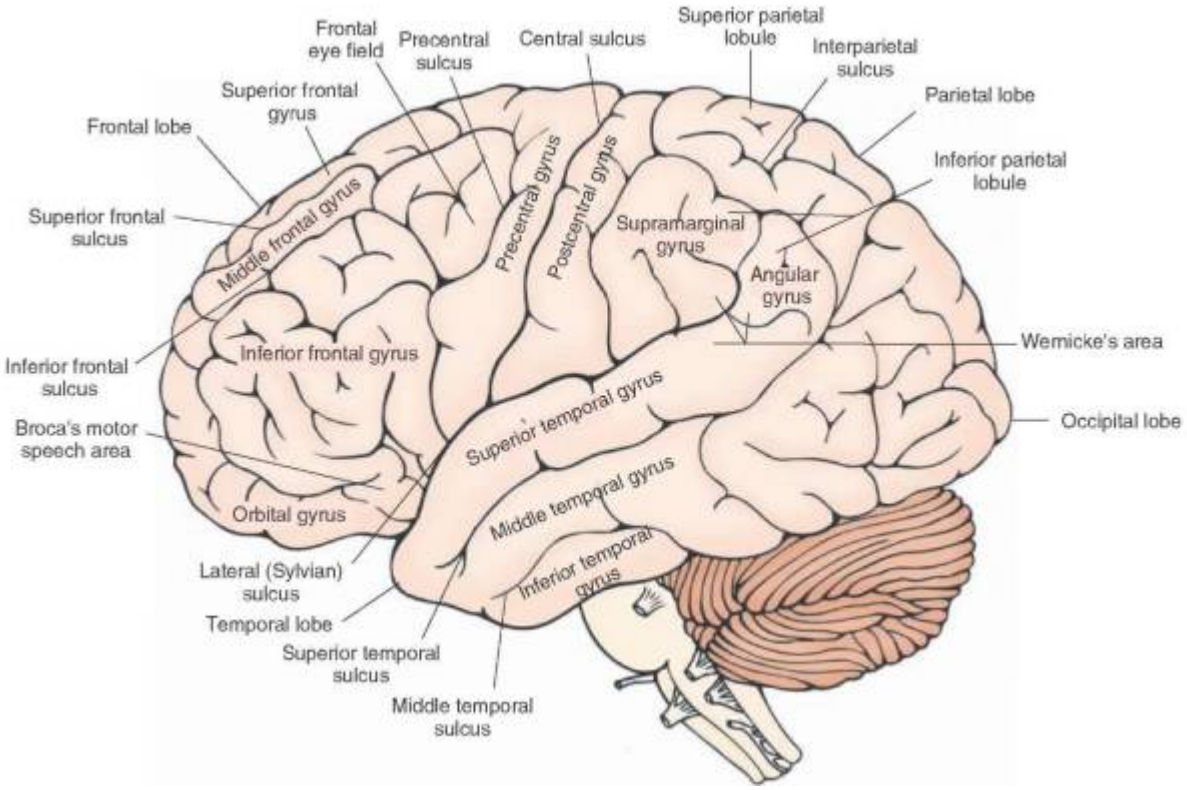

The central sulcus is a fold in the cerebral cortex in the brains of vertebrates. Also called the central fissure, it was originally called the fissure of Rolando or the Rolandic fissure, after Luigi Rolando. It is sometimes confused with the medial longitudinal fissure.

The central sulcus is a prominent landmark of the brain, separating the parietal lobe from the frontal lobe and the primary motor cortex from the primary somatosensory cortex.

The central sulcus joins the Sylvian fissure in only 2 % of cases (i.e., in 98% of cases there is a subcentral gyrus).

During neurosurgical procedures, it is sometimes difficult to understand the cortical anatomy of this region.

In 68/82 hemispheres, the central sulcus did not reach the posterior ramus of the lateral sulcus. A knob on the second curve of the precentral gyrus was reliably identified in only 64/82 hemispheres [1].

Location

Central sulcus location.

Pathology

Focal cortical dysplasias (FCDs) are mainly located in the frontal region, with a particular tropism for the central sulcus.

References

[1]
Rodrigues T, Rodrigues M, Paz D, Costa MD, Santos B, Braga V, Paiva Neto Md, Centeno R, Cavalheiro S, Chaddad-Neto F. Is the omega sign a reliable landmark for the neurosurgical team? An anatomical study about the central sulcus region. Arq Neuropsiquiatr. 2015 Nov;73(11):934-8. doi: 10.1590/0004-282×20150160. PubMed PMID: 26517217.

From:
https://neurosurgerywiki.com/wiki/ - **Neurosurgery Wiki**

Permanent link:
https://neurosurgerywiki.com/wiki/doku.php?id=central_sulcus

Last update: **2025/04/29 20:27**