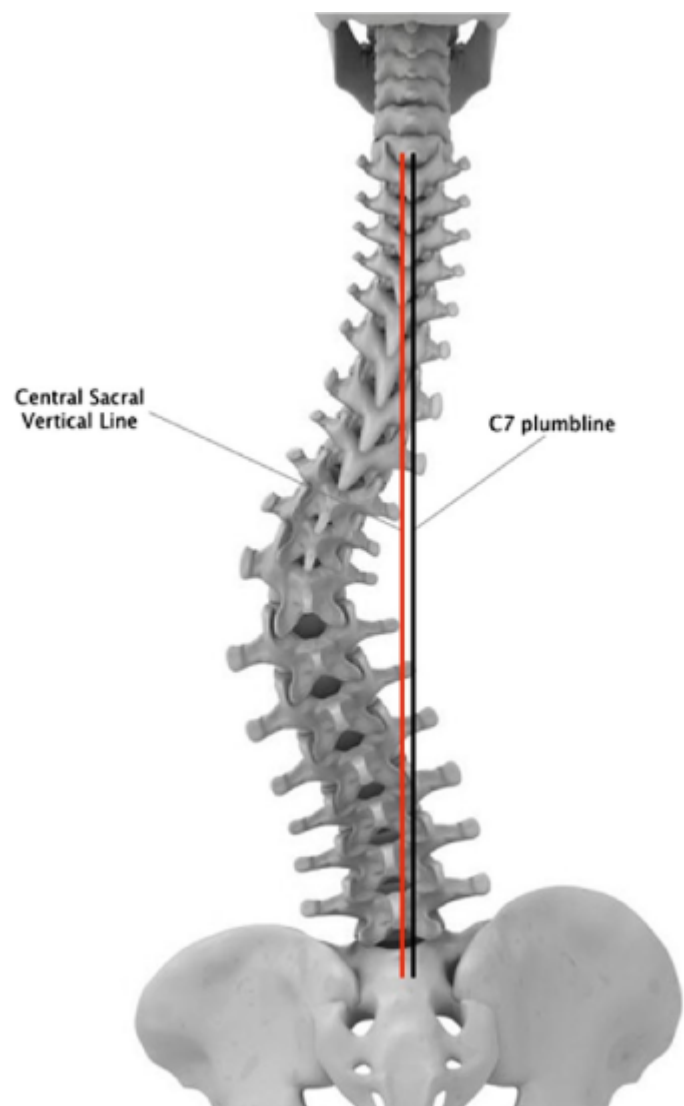


Central Sacral Vertical Line



(On AP standing scoliosis x-ray) vertically oriented line which bisects the sacrum perpendicular to a tangent drawn across the iliac crests.

The central sacral vertical line (CSVL) is used in the assessment of spinal scoliosis.

It is a line constructed on frontal films of the spine and pelvis to measure coronal balance, drawn as follows:

a line connecting the top of the iliac crests is drawn

a second line is drawn perpendicular to the first, which bisects the sacrum.

Normal: For coronal balance, a plumb line from the middle of C7 VB should be < 4 cm from [CSVL](#).

Alignment objective: Plumb line from the middle of C7 VB < 4 cm from CSVL.

Positive numbers are to the right, negative to left.

From:

<https://neurosurgerywiki.com/wiki/> - **Neurosurgery Wiki**

Permanent link:

https://neurosurgerywiki.com/wiki/doku.php?id=central_sacral_vertical_line

Last update: **2024/06/07 02:55**

