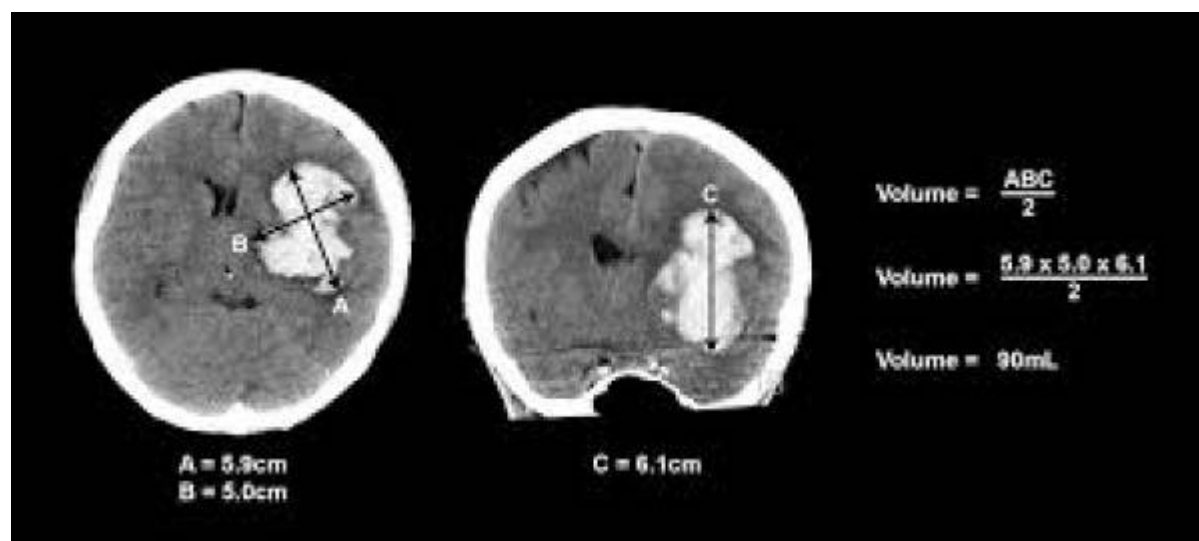


ABC/2



A is the greatest diameter by [CT](#), B is the diameter 90 degrees to A, and C is the approximate number of [CT](#) slices with hemorrhage multiplied by the [slice thickness](#).

Intracerebral hemorrhage

The ABC/2 method for calculating intracerebral hemorrhage (ICH) [volume](#) has been well validated. However, the formula, derived from the volume of an ellipse, assumes the shape of ICH is elliptical.

Although the ABC/2 formula for calculating elliptical ICH is well validated, it must be used with caution in ICH scans where the elliptical shape of ICH is a false assumption.

Haley et al., validated the adjustment of the ABC/2.4 method in randomization, antithrombotic-associated, heterogeneous-density, and irregular-shape ICH ¹⁾.

The ICH volumes for 118 patients were evaluated in a mean of 38 seconds and correlated with planimetric measurements ($R^2 = 9.6$). Interrater and intrarater reliability were excellent, with an intraclass correlation of .99 for both.

Kothari et al., conclude that ICH volume can be accurately estimated in less than 1 minute with the simple formula ABC/2 ²⁾.

Rapid calculation of ICH volume at the time of initial patient presentation has clinical utility. For prognosis, a model of 30-day mortality that used the Glasgow Coma Scale and hemorrhage volume in patients with ICH correctly predicted outcome with a sensitivity and specificity of 97%.

The ABC/2 technique may also be used to identify appropriate patients with ICH suitable for randomization into therapeutic trials.

For example, the technique is the measurement method used for patient eligibility assessment in the

multicenter Surgical Trial of Intracerebral Hemorrhage (J. Grotta, unpublished data, 1996). In this trial, patients with ICH and anticipated good outcome are not eligible for surgery. Thus, patients with hemorrhage volumes of less than 10 cm³ and patients with lobar hemorrhage volumes of 10 to 20 cm³ with minimal or no neurological deficits are excluded.

Lisk and colleagues demonstrated the ease and power of the ABC/2 method of volume measurement in a model of outcome after ICH but did not correlate this technique with other methods of volume measurement. The ABC/2 formula can be adjusted for CT slices of varying thickness by multiplying the number of slices of the different thicknesses on which the hematoma is seen (C of ABC/2) by the slice thickness in centimeters. Other authors have estimated hematoma volume by assuming it to approximate the volume of a sphere, an ellipsoid, or a rectangulopiped.

Only estimates of volume that use the formula for an ellipsoid have been shown to correlate with planimetric techniques.

This rapid method of measuring hemorrhage volume may allow physicians to quickly select and stratify patients in future treatment trials ³⁾.

Meningioma

Measurement of tumor growth rates over time for patients with [meningiomas](#) has important prognostic and therapeutic implications. The objective of Opalak et al. was to compare two methods of measuring meningioma volume: (1) the simplified ellipsoid (ABC/2) method; and (2) perimetric volume measurements using imaging software modules.

Patients with conservatively managed meningiomas for at least 1.5 years were retrospectively identified from the VCU Brain and Spine Tumor Registry over a 10-year period (2005-2015). Tumor volumes were independently measured using the simplified ellipsoid and computerized perimetric methods. Intra class correlations (CC) and Bland-Altman analyses were performed.

A total of 26 patients representing 29 tumors were identified. Across 146 images, there were 24 (16%) images that were non-measurable using standard application commands with the computerized perimetric method. The mean volume obtained using the ABC/2 and computerized perimetric methods were 3.2 ± 3.4 cm³ and 3.4 ± 3.5 cm³, respectively. The mean volume difference was 0.2 cm³ (SE = 0.12; p = 0.10) across measurement methods. The concordance correlation coefficient (CCC) between methods was 0.95 (95% CI 0.91, 0.98).

There is excellent correlation between the simplified ellipsoid and computerized perimetric methods of volumetric analysis for conservatively managed meningiomas. The simplified ellipsoid method remains an excellent method for meningioma volume assessment and had an advantage over the perimetric method which failed to allow measurement of roughly one in six tumors on imaging ⁴⁾.

Vestibular schwannoma

see [Vestibular schwannoma volume](#).

Epidural hematoma

The ABC/2 method could be used for [epidural hematoma](#) volume EDHV measurement, which would contribute to treatment decision making as well as clinical outcome prediction. However, clinicians should be aware that the ABC/2 method results in a general volume overestimation. Future studies focusing on justification of the technique to improve its accuracy would be of practical value ⁵⁾.

Pneumocephalus volume

An excellent correlation is observed between the [ABC/2](#) method and the computer-assisted measurement. This study verified that the ABC/2 method is an accurate and simple “bedside” technique to estimate [pneumocephalus](#) volume ⁶⁾.

References

1)

Haley MD, Gregson BA, Mould WA, Hanley DF, Mendelow AD. Retrospective Methods Analysis of Semiautomated Intracerebral Hemorrhage Volume Quantification From a Selection of the STICH II Cohort (Early Surgery Versus Initial Conservative Treatment in Patients With Spontaneous Supratentorial Lobar Intracerebral Haematomas). *Stroke*. 2018 Feb;49(2):325-332. doi: 10.1161/STROKEAHA.117.016677. Epub 2018 Jan 10. PubMed PMID: 29321340.

2) , 3)

Kothari RU, Brott T, Broderick JP, Barsan WG, Sauerbeck LR, Zuccarello M, Khoury J. The ABCs of measuring intracerebral hemorrhage volumes. *Stroke*. 1996 Aug;27(8):1304-5. PubMed PMID: 8711791.

4)

Opalak CF, Parry M, Rock AK, Sima AP, Carr MT, Chandra V, Workman KG, Somasundaram A, Broaddus WC. Comparison of ABC/2 estimation and a volumetric computerized method for measurement of meningiomas using magnetic resonance imaging. *J Neurooncol*. 2019 Aug 10. doi: 10.1007/s11060-019-03205-z. [Epub ahead of print] PubMed PMID: 31401721.

5)

Hu TT, Yan L, Yan PF, Wang X, Yue GF. Assessment of the ABC/2 Method of Epidural Hematoma Volume Measurement as Compared to Computer-Assisted Planimetric Analysis. *Biol Res Nurs*. 2015 Mar 23. pii: 1099800415577634. [Epub ahead of print] PubMed PMID: 25802386.

6)

Chan DYC, Cheung EYH, Hui KH, Leung CMS, Ng SCP, Mak WK, Wong GKC, Chan TMD, Poon WS. ABC/2 formula for “bedside” postoperative pneumocephalus volume measurement. *Chin Neurosurg J*. 2022 Aug 3;8(1):18. doi: 10.1186/s41016-022-00287-z. PMID: 35922864.

From:

<https://neurosurgerywiki.com/wiki/> - **Neurosurgery Wiki**

Permanent link:

https://neurosurgerywiki.com/wiki/doku.php?id=abc_2

Last update: **2024/06/07 02:59**

